

CASE REPORT

Open Access



Familial dysalbuminemic hyperthyroxinemia combined with Graves' disease: a rare case report

Yuanmeng Li^{1,2†}, Yue Chi^{1,2†}, Xiaofeng Chai^{1,2}, He Liu^{1,2}, Naishi Li^{1,2,3,4*} and Xiaolan Lian^{1,2*}

Abstract

Background Familial dysalbuminemic hyperthyroxinemia (FDH) is an autosomal dominant disease characterised by an abnormally increased affinity of albumin for serum thyroxine. Assay interference and differential diagnosis remain challenging for FDH. The condition is more complicated when FDH is combined with primary thyroid diseases. Co-occurrence of FDH and Graves' disease is rare.

Case presentation We report the case of a 28-year-old woman with complex FDH and coexisting Graves' disease. Initially, the existence of FDH was not recognised. Graves' disease was relieved after treatment with antithyroid drugs and two administrations of radioactive iodine therapy. She subsequently developed primary hypothyroidism and was prescribed levothyroxine replacement. However, thyroid function failed to normalise despite frequent levothyroxine dose adjustments. Ultimately, syndromes involving the inappropriate secretion of thyroid-stimulating hormone (IST) were considered, and FDH was successfully differentiated from other causes of IST.

Conclusions A greater focus on FDH when investigating the causes of IST is critical to correctly evaluate thyroid function status and avoid inappropriate treatment, especially in complicated cases with concurrent FDH and primary thyroid diseases.

Keywords Familial dysalbuminemic hyperthyroxinemia, Graves' disease, Syndromes of inappropriate secretion of thyroid stimulating hormone, Hypothyroidism, Case report

[†]Yuanmeng Li and Yue Chi contributed equally to this work.

*Correspondence:

Naishi Li

LNS@medmail.com.cn

Xiaolan Lian

lianlanx@126.com

¹ Department of Endocrinology, Key Laboratory of Endocrinology of National Health Commission, Peking Union Medical College Hospital, Chinese Academy of Medical Sciences & Peking Union Medical College, Beijing, China

² State Key Laboratory of Complex Severe and Rare Diseases, Peking Union Medical College Hospital, Chinese Academy of Medical Sciences & Peking Union Medical College, Beijing, China

³ Department of Medical Records, Peking Union Medical College Hospital, Chinese Academy of Medical Sciences & Peking Union Medical College, Beijing, China

⁴ WHO Family of International Classifications Collaborating Center of China, Beijing, China

Background

Familial dysalbuminemic hyperthyroxinemia (FDH) is an autosomal dominant disorder caused by mutations in the albumin gene (*ALB*) that results in an abnormally increased affinity of albumin for serum thyroxine (T₄). Patients with FDH are physiologically euthyroid despite of the increased levels of circulating total thyroxine (TT₄). With an estimated prevalence of 1 in 10 000 individuals, FDH is the predominant form of euthyroid hyperthyroxinemia within the Caucasian population [1]. However, FDH is clinically underdiagnosed, in part because it can mimic the thyroid function profiles of thyroid hormone resistance syndrome (RTH) and thyroid stimulating hormone (TSH)-secreting pituitary adenomas (TSHomas), making the differential diagnosis



difficult. A few cases of concurrent FDH and Graves' disease (GD) have been reported. The coexistence of these two conditions further complicates the diagnosis and hinders appropriate treatment.

Herein, we describe a complex case of FDH combined with GD. After receiving antithyroid drugs and two rounds of radioactive iodine (RAI) therapy, GD was relived, and subsequent treatment for hypothyroidism was initiated. However, proper diagnosis and treatment were substantially delayed because of the complicated fluctuations in thyroid function.

The purpose of this article is to analyse the differentiation of FDH from RTH and TSHomas and to summarise the characteristics of FDH combined with GD.

Case presentation

A 28-year-old Chinese woman was found to have abnormal thyroid function tests following routine testing in May 2017. The thyroid function test (Chemiluminescence immunoassay, Roche, one-step method) results were: free thyroxine (FT4) 1.97 ng/dL (reference range 0.58–1.64), free triiodothyronine (FT3) 4.42 pg/mL (reference range 2.39–4.2), TSH 2.060 μ IU/mL (reference range 0.34–6.05). The patient did not receive any treatment since she had no thyrotoxic symptoms. Thyroid function tests (Chemiluminescence immunoassay, Siemens, one-step method) were repeated in June 2018 in a local laboratory: TT4 13.6 μ g/dL (reference range 4.3–12.5), total triiodothyronine (TT3) 1.28 ng/mL (reference range 0.6–1.81), TSH 0.19 μ IU/mL (reference range 0.35–5.5). Still, the patient did not visit any other hospitals because she had no symptoms. However, in March 2019, the patient developed palpitations, increased hunger, polyphagia, increased stool frequency, and weight loss. Thyroid function tests were repeated and listed as follows: FT4 3.48 ng/dL (reference range 0.7–1.48), FT3 16.65 pg/mL (reference range 1.58–3.91), TSH < 0.005 μ IU/mL (reference range 0.35–4.94), and the anti-TSH receptor antibody (TRAb) level was significantly elevated (11.66 IU/L). GD was diagnosed, and the patient received methimazole therapy at a dose of 30 mg per day. The thyroid function tests were repeated when the thyrotoxicosis did not improve after one month: FT4 6.73 ng/dL (reference range 0.93–1.7), FT3 12.19 pg/mL (reference range 2.0–4.4), TSH < 0.005 μ IU/mL (reference range 0.27–4.2). As the patient was concerned that a longer course of methimazole therapy might delay her pregnancy planning, she decided to change treatment. RAI therapy was initiated in May 2019. The RAI dose was 5 millicurie (mCi), mainly based on the weight of the thyroid estimated by nuclide scanning and the iodine uptake rate. Five months later, re-evaluation of thyroid function revealed a persistently elevated serum FT4 level and an

enduring reduction in serum TSH level: FT4 2.13 ng/dL (reference range 0.93–1.7), FT3 4.4 pg/mL (reference range 2–4.4), TSH < 0.005 μ IU/mL. As the patient was anxious to prepare for pregnancy, she elected to discontinue observation and undergo a second round of RAI therapy, which was initiated in November 2019 with a dose of 4.62 mCi. Prednisone was not used during the two rounds of RAI therapy.

In January 2020, the patient experienced fatigue and weight gain. Repeated thyroid function test revealed as follows: FT4 0.65 ng/dL (reference range 0.93–1.7), FT3 1.57 pg/mL (reference range 2–4.4), TSH 14.71 μ IU/mL. At this point, she was prescribed levothyroxine with a dosage gradually increased to 125 μ g (1.92 μ g/kg) per day. The thyroid function test results in June 2020 were as follows: FT4 3.05 ng/dL (reference range 0.59–1.25), FT3 2.83 pg/mL (reference range 2.14–4.21), TSH 0.07 mIU/L (reference range 0.56–5.91). On advice at the local hospital, the patient stopped taking levothyroxine. One month later, the patient developed fatigue again and visited the outpatient department of our hospital. Levothyroxine replacement was restarted; however, the dosage required frequent adjustments because of difficulty achieving normal thyroid function test results. A summary of the patient's clinical course is presented in Fig. 1.

The patient was healthy, married, and childless. The patient's father had consistently abnormal thyroid tests in May 2020 and December 2021, with results as follows: In May 2020, FT4 was 36.24 pmol/L (reference range 12–22), FT3 was 6.4 pmol/L (reference range 3.1–6.8), and TSH was 1.98 μ IU/mL (reference range 0.27–4.2). In December 2021, FT4 was 35.75 pmol/L (reference range 6.44–18.02), FT3 was 5.70 pmol/L (reference range 2.76–6.45), and TSH was 2.608 μ IU/mL (reference range 0.35–5.1). The father remained asymptomatic and untreated. The patient's mother had normal thyroid function. Additionally, an uncle and an aunt had a history of hyperthyroidism but achieved remission with methimazole treatment; their thyroid function test results in December 2021 were within normal limits (Fig. 2).

Investigation

In December 2021, the patient was admitted to our hospital. Thyroid function tests were performed simultaneously using two different immunoassay methods (Centaur, one-step method; Abbott, two-step method), and the results were largely consistent (Table 1). The TRAb level was elevated to 10.48 IU/L (reference range < 2.5), whereas the antithyroid peroxidase antibody, antithyroglobulin antibody, and thyroglobulin levels were all within the normal ranges.

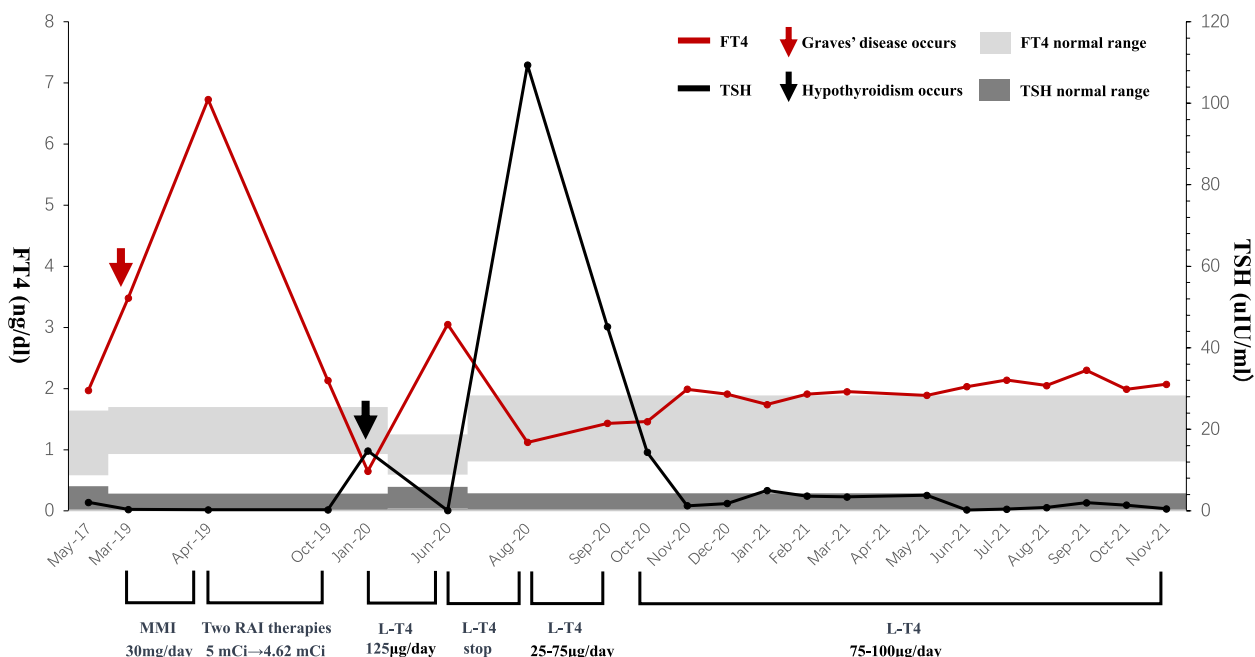


Fig. 1 A summary of the patient’s clinical course. FT4, free thyroxine; TSH, thyroid stimulating hormone; MMI, methimazole; RAI, radioactive iodine; mCi, millicurie; L-T4, levothyroxine

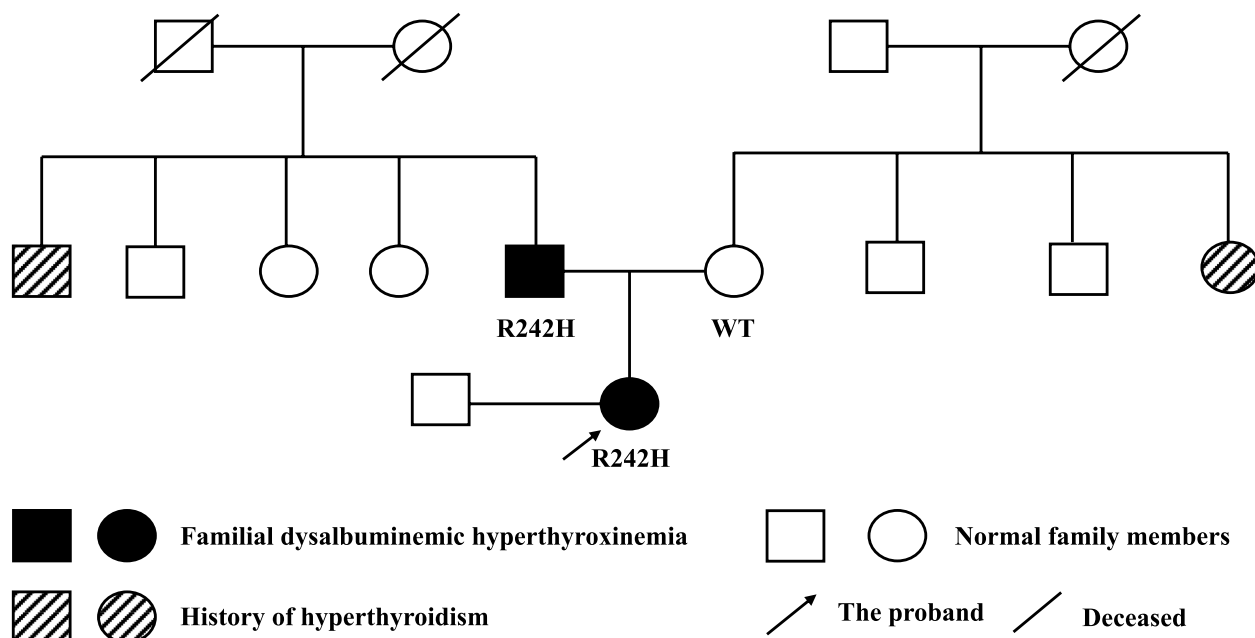


Fig. 2 The family pedigree of the patient

TSHomas and RTH were further investigated for the differential diagnosis. The exact data were listed as follows: sex hormone binding globulin (SHBG) 49.7 nmol/L (18.2–135.5), serum iron 61 µg/dL (50–170), ferritin 6 ng/mL (14–307). The levels of anterior pituitary

hormones were within normal limits, and the dynamic contrast-enhanced magnetic resonance imaging (MRI) of the pituitary showed no signs of a pituitary tumour. In the somatostatin analogue test using Sandostatin (Novartis, Switzerland), the suppression ratios of TSH at

Table 1 Results of simultaneous thyroid function tests using different methods

	FT4	FT3	TT4	TT3	TSH	Detection date and treatment
One-step method (Centaur)	2.03 ng/dL (0.81–1.89)	4.55 pg/mL (1.8–4.1)	20.20 µg/dL (4.3–12.5)	1.34 ng/mL (0.66–1.92)	0.232 µIU/mL	Detected on 06/16/21, while on 1.43 µg/kg levothyroxine daily, 19 months following the second dose of the radioactive iodine
Two-step method (Abbott)	1.52 ng/dL (0.70–1.48)	1.06 ng/mL (0.58–1.59)	14.51 µg/dL (4.84–11.72)	3.46 pg/mL (1.71–3.71)	0.305 µIU/mL	

Table 2 Results of the somatostatin analogue test

The somatostatin analogue test	0 h	2 h	4 h	6 h	8 h	24 h	48 h	72 h
TSH (µIU/mL)	1.041	0.471	0.307	0.252	0.329	0.204	0.235	0.244
FT3(pg/mL)	3.53	3.76	3.70	3.57	3.51	3.34	3.14	2.86
FT4(ng/dL)	1.91	2.10	1.91	1.74	1.92	1.68	1.62	1.68

Methods of the somatostatin analogue test: Somatostatin analogue was administered subcutaneously nine times at a dosage of 100 µg every 8 h. Serum TSH, FT3 and FT4 levels were measured at 0, 2, 4, 6, 8, 24, 48, and 72 h after the first injection

24 h versus 0 h and 2 h were determined to be 80.4% and 56.7%, respectively (Table 2).

As the patient had no symptoms of hypermetabolism, showed normal levels of SHBG, and lacked signs of adenoma on pituitary MRI, the diagnosis of TSHomas was excluded, despite the supportive result of

the somatostatin analogue test. Considering that the patient and her father had similar thyroid dysfunction, whole-exome sequencing was performed on the patient’s peripheral blood. A heterozygous mutation at exon 7 (c.725G > A) of the *ALB* gene was discovered

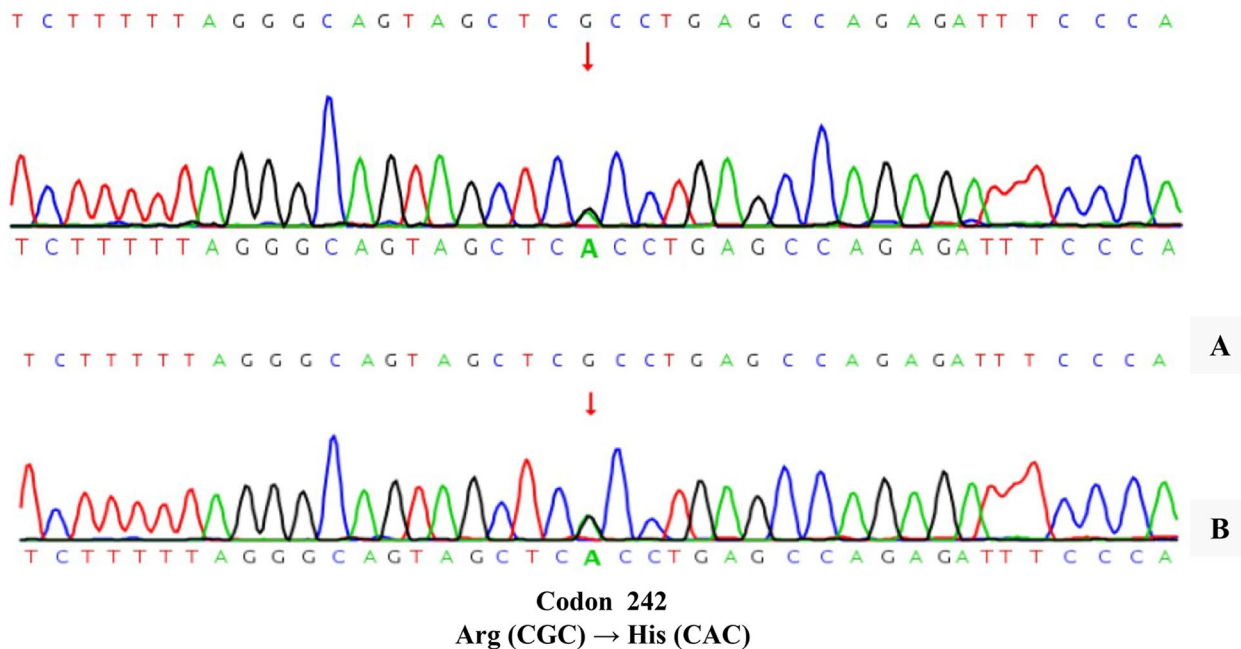


Fig. 3 Gene sequencing of the patient (A). Confirmed results in the patient’s father by Sanger sequencing (B)

(Fig. 3A), which was also verified in her father by Sanger sequencing (Fig. 3B).

Discussion and conclusions

FDH was first reported by Hennemen et al. and Lee et al. in 1979 [2, 3]. Since then, the underlying pathogenesis of FDH has gradually been elucidated. Because of the increased affinity of mutant albumin for thyroxine, TT4 levels are elevated in patients with FDH. Theoretically, FT4 levels should not be affected. In fact, the FT4 value is characteristically within normal limits if direct assays such as equilibrium dialysis and ultrafiltration are used [4].

However, direct assays are rarely used in clinical practice because of limitations including high technical requirements and costs. Chemiluminescence immunoassay, a method that relies on the competition between T4 analogues and unbound T4 to determine the level of FT4, is the most commonly used technique. In patients with FDH, the chemiluminescence immunoassay is affected by the enhanced binding of mutant albumin to T4 analogues, resulting in falsely elevated FT4 values. Some studies have attempted to solve this problem by adding an additional washing step to avoid contact between T4 analogues and serum albumin, the so-called two-step method [5]. However, Khoo et al. revealed the potential for misleading results with falsely elevated FT4 levels using both one-step and two-step immunoassay methods [6]. Furthermore, they concluded that the varying susceptibility of FT4 to interference in different assays was likely attributable to differences in assay conditions and buffer composition, rather than being associated with assay architecture [6]. In the present case, circulating FT4 levels measured by the Centaur (one-step method) and Abbott (two-step method) methods were both elevated to a similar extent. These findings suggest that it is unreliable to assess the diagnosis of FDH solely by comparing changes in FT4 values measured using the one-step and two-step methods.

Diagnostic difficulties for FDH lie not only in the interference of detection assays but also in the differential diagnosis from other causes of the inappropriate secretion of thyroid-stimulating hormone (IST), especially RTH and TSHomas. RTH is an inherited disorder characterised by impaired sensitivity of targeted tissues to thyroid hormones. The majority of cases involve resistance to thyroid hormone β (RTH β), caused by mutations in the thyroid hormone receptor β gene. FDH can mimic the typical thyroid function profile of RTH. By summarising the characteristics of RTH β and FDH, Dieu et al. proposed that if a patient is asymptomatic and the circulating FT3 value is less than 1.11 times the upper limit

of the reference range, the diagnosis is more likely FDH than RTH β [7]. Their conclusions are applicable to the present case.

For patients suspected of having TSHomas, signs of adenoma on pituitary imaging and a positive somatostatin analogue test result can support the diagnosis. Han et al. proposed a cut-off point of 44.46% (suppression ratio of TSH at 24 h versus 2 h) for the differential diagnosis of TSHomas and other causes of IST (mainly RTH β) [8]. In the case of our patient, the somatostatin analogue test was conducted with the intention of distinguishing between TSHomas and RTH β . While the results initially reached the TSHomas diagnosis threshold, the ultimate diagnosis was FDH. Considering the expected normal TSH secretion in FDH patients, it is theoretically reasonable to expect that the somatostatin test results would resemble those of healthy individuals, even though there is no definitive data on how healthy individuals react to this test. Therefore, while the somatostatin test may be a valuable tool in distinguishing between TSHomas and RTH β , its utility in identifying FDH may be limited.

In terms of incidence, RTH occurs in approximately 1 in 40 000 live births [9], and TSHomas are estimated to affect 1 in 1 000 000 individuals [10]. In contrast, FDH exhibits a relatively high incidence rate of 1 in 10 000 [1]. However, prior research efforts related to IST has predominantly focused on the identification of RTH β and TSHomas. In fact, according to established guidelines, FDH should be excluded as a possibility before considering RTH and TSHomas [11]. Specifically, when faced with elevated thyroid hormone levels and non-suppressed TSH levels, the initial investigative step should involve the exclusion of potential methodological interferences. These interferences may include the presence of circulating heterophilic antibodies, anti-iodothyronine auto-antibodies, and anomalies of albumin (i.e., FDH) or transthyretin [11]. Therefore, prior to distinguishing TSHomas from RTH β , we recommend heightened awareness of assay interferences, especially the potential involvement of FDH.

The coexistence of FDH and GD is uncommon. A few studies have briefly described cases of FDH combined with GD. Young reported a 50-year-old woman with concurrent FDH and GD in 1987 [12]. Jones reported that a 17-year-old female individual who presented with FDH and GD presented postpartum [13]. Khoo described a 42-year-old woman with both Hashimoto's thyroiditis and GD in the setting of FDH [14]. Including the present case, all reported patients with FDH complicated by GD have been female. Regarding the treatment of GD in previous cases, one patient received RAI therapy and developed hypothyroidism, while two were prescribed

antithyroid drugs. One patient quickly developed hypothyroidism, while the other achieved normal TSH levels within eight months.

In the present case, the treatment was more complex. Methimazole was initially administered but did not improve hyperthyroidism after one month. Because the patient was concerned that a longer course of methimazole therapy might delay her pregnancy planning, RAI therapy was then administered, and a thyroid function test after five months showed that the FT4 level was slightly elevated, the FT3 level was nearly within normal limits, and the TSH level was still significantly reduced. Furthermore, because the patient needed to prepare for pregnancy as soon as possible, a second RAI therapy was administered, and hyperthyroidism was eventually ameliorated. The patient developed hypothyroidism after receiving RAI therapy for GD. Because of the undiagnosed FDH, thyroid function failed to normalise despite frequent levothyroxine adjustments. In one instance, levothyroxine therapy was inappropriately discontinued at the local hospital. In fact, the levothyroxine dosage should only be adjusted based on TSH levels in patients with coexisting FDH and hypothyroidism [14]. Overall, from this case we learned that early recognition of FDH is helpful for the management of concomitant GD or hypothyroidism.

The patient in this case report was a woman of child-bearing age with reproductive aspirations. It is generally believed that patients with FDH can become pregnant without any special intervention. For pregnancy complicated by FDH, excluding thyrotoxicosis is critical to avoid unnecessary treatment and its impact on the foetus [15]. A recent study found that the R218S variant of FDH might be related to high miscarriage rates [16], suggesting that pregnant patients with R218S mutation should be alert to adverse pregnancy outcomes.

In conclusion, FDH causes a similar pattern of thyroid hormone biochemistry to that of TSHomas and RTH β and is an underdiagnosed cause of assay interference. Therefore, it is important to pay more attention to FDH when analysing the causes of IST. The coexistence of FDH and GD is rare and significantly complicates the disease management. Failure to identify FDH early can easily lead to misinterpretation of the thyroid function status and inappropriate treatment.

Abbreviations

FDH	Familial dysalbuminemic hyperthyroxinemia
ALB	Albumin gene
T4	Thyroxine
TT4	Total thyroxine
RTH	Thyroid hormone resistance syndrome
TSH	Thyroid stimulating hormone
TSHomas	TSH-secreting pituitary adenomas

GD	Graves' disease
RAI	Radioactive iodine
FT4	Free thyroxine
FT3	Free triiodothyronine
TT3	Total triiodothyronine
TRAb	Anti-TSH receptor antibody
mCi	MilliCurie
SHBG	Sex hormone binding globulin
MRI	Magnetic resonance imaging
IST	Inappropriate secretion of thyroid stimulating hormone
RTH β	Resistance to thyroid hormone β

Acknowledgements

We thank the patient for the report. We would have been unable to complete the study without participation.

Authors' contributions

YL collected the patient data and wrote the article. YC analyzed and interpreted the patient data. XC and HL participated in the clinical management of the patient and analyzed the patient data. NL and XL reviewed and edited the article. All authors read and approved the final manuscript.

Funding

This work was supported by the Chinese Academy of Medical Sciences (CAMS) Innovation Fund for Medical Science (CIFMS; No. 2021-1-I2M-022).

Availability of data and materials

All data generated or analysed during this study are included in this published article.

Declarations

Ethics approval and consent to participate

The study was approved by the Peking Union Medical College Hospital Ethics Committee. Written informed consent was obtained from the patient.

Consent for publication

Written informed consent for the publication of their clinical details and/or clinical images was obtained from the patient. A copy of the consent form is available for review by the Editor of this journal.

Competing interests

The authors declare no competing interests.

Received: 10 February 2023 Accepted: 8 October 2023

Published online: 18 October 2023

References

- Kragh-Hansen U, Galliano M, Minchiotti L. Clinical, Genetic, and Protein Structural Aspects of Familial Dysalbuminemic Hyperthyroxinemia and Hypertriiodothyroninemia. *Front Endocrinol (Lausanne)*. 2017;8:297.
- Hennemann G, Docter R, Krenning EP, Bos G, Otten M, Visser TJ. Raised total thyroxine and free thyroxine index but normal free thyroxine. A serum abnormality due to inherited increased affinity of iodothyronines for serum binding protein. *Lancet*. 1979;1(8117):639–42.
- Lee WN, Golden MP, Van Herle AJ, Lippe BM, Kaplan SA. Inherited abnormal thyroid hormone-binding protein causing selective increase of total serum thyroxine. *J Clin Endocrinol Metab*. 1979;49(2):292–9.
- Cartwright D, O'Shea P, Rajanayagam O, Agostini M, Barker P, Moran C, et al. Familial dysalbuminemic hyperthyroxinemia: a persistent diagnostic challenge. *Clin Chem*. 2009;55(5):1044–6.
- Spencer CA. Assay of Thyroid Hormones and Related Substances. In: Feingold KR, Anawalt B, Boyce A, Chrousos G, de Herder WW, Dhatariya K, et al., editors. *Endotext*. South Dartmouth: MDText.com, Inc. Copyright © 2000–2022, MDText.com, Inc.; 2000.
- Khoo S, Lyons G, McGowan A, Gurnell M, Oddy S, Visser WE, et al. Familial dysalbuminaemic hyperthyroxinaemia interferes with current

- free thyroid hormone immunoassay methods. *Eur J Endocrinol*. 2020;182(6):533–8.
7. Dieu X, Bouzamondo N, Briet C, Illouz F, Moal V, Boux de Casson F, et al. Familial Dysalbuminemic Hyperthyroxinemia: An Underdiagnosed Entity. *J Clin Med*. 2020;9(7):2105.
 8. Han R, Shen L, Zhang J, Xie J, Fang W, Sun Q, et al. Diagnosing Thyrotropin-Secreting Pituitary Adenomas by Short-Term Somatostatin Analogue Test. *Thyroid*. 2020;30(9):1236–44.
 9. Dumitrescu AM, Refetoff S. The syndromes of reduced sensitivity to thyroid hormone. *Biochem Biophys Acta*. 2013;1830(7):3987–4003.
 10. Amlashi FG, Tritos NA. Thyrotropin-secreting pituitary adenomas: epidemiology, diagnosis, and management. *Endocrine*. 2016;52(3):427–40.
 11. Beck-Peccoz P, Lania A, Beckers A, Chatterjee K, Wemeau JL. 2013 European thyroid association guidelines for the diagnosis and treatment of thyrotropin-secreting pituitary tumors. *Eur Thyroid J*. 2013;2(2):76–82.
 12. Young RA, Stoffer SS, Braverman LE. Familial dysalbuminemic hyperthyroxinemia associated with primary thyroid disease. *Am J Med*. 1987;82(2):221–3.
 13. Jones A, Hopton MR, Gurling KJ, Harrop JS. Iatrogenic hypothyroidism and postpartum hyperthyroidism in familial dysalbuminaemic hyperthyroxinaemia. *Br Med J (Clin Res Ed)*. 1987;294(6567):286.
 14. Khoo S, Lyons G, Solomon A, Oddy S, Halsall D, Chatterjee K, et al. Familial dysalbuminemic hyperthyroxinemia confounding management of coexistent autoimmune thyroid disease. *Endocrinol Diabetes Metab Case Rep*. 2020;2020:19-0161.
 15. Sachmechi I, Schussler GC. Familial dysalbuminemic hyperthyroxinemia in pregnancy. *Eur J Endocrinol*. 1995;133(6):729–31.
 16. Lai S, Gopalakrishnan G, Li J, Liu X, Chen Y, Wen Y, et al. Familial Dysalbuminemic Hyperthyroxinemia (FDH), Albumin Gene Variant (R218S), and Risk of Miscarriages in Offspring. *Am J Med Sci*. 2020;360(5):566–74.

Publisher's Note

Springer Nature remains neutral with regard to jurisdictional claims in published maps and institutional affiliations.

Ready to submit your research? Choose BMC and benefit from:

- fast, convenient online submission
- thorough peer review by experienced researchers in your field
- rapid publication on acceptance
- support for research data, including large and complex data types
- gold Open Access which fosters wider collaboration and increased citations
- maximum visibility for your research: over 100M website views per year

At BMC, research is always in progress.

Learn more biomedcentral.com/submissions

